

## Removal of the internal fixation after 12 months in patients with traumatic fractures of the thoracic and lumbar spine: A retrospective evaluation.

Munzir J. M. Al-Zabin

Department of Neurosurgery, Neurosurgical Intensive Care, Emergency Medicine and Radiological Protection, Gulf Medical College Hospital and Research Centre, Ajman, UAE.

### ABSTRACT

**Objective:** Patients with monosegmental traumatic fractures of the thoracic and lumbar spine have been operated with an internal fixation. A retrospective evaluation of our cases between 2005 and 2011 in Magdeburg (Germany) were performed due to the clinical course and follow-up after the removal of the internal fixation after approximately 12 months.

**Materials and Methods:** Between 2005 and 2011 patients with dorsal fractures (51 cases: 28 thoracic, 23 lumbar) have been treated, whereas performed a dorsal approach and implantation of an internal fixator have been performed. The removal of the internal fixation (second surgery) was approximately after 12 months. The mean age was 42 years, 29 males, 22 females.

**Results:** Prior to the second surgery 9 patients had pain >50 on VAS, Motor deficits 6 prior and 5 after surgery. 8 Patients had sensory deficits prior, but just 6 after the 2. surgery. No myelopathy had been occurred. Ability to work after the 2. surgery: 24 full time, 12 part time, 7 unable to work and 7 retired. Back to work ratio 86%. About 29 out of 51 patients were available for re-examination and interview 6 months after the explanation of the internal fixation. 27 were happy with the outcome. Radiological findings after the second surgery: No signs of instability in 49 patients, in 2 patients with fixation in the thoracic spine slightly compression of the vertebral bodies without a surgical consequence has been observed.

**Complications:** In two patients with rebleeding requiring surgical evacuation on the day of surgery. Uneventful further recovery. So far no single case of infection.

**Conclusions:** In our cases the explantation of the thoracic and lumbar internal fixation is not associated with an increased risk for the patients as compared to not removal of this fixation and it appears to be particularly practicable in younger age groups up to 65 years. The long term effect of this operation technique is unclear as of yet.

**Key word:** thoraco-lumbar fracture, internal fixation, elective operation, spondylodesis.

### INTRODUCTION

In the literature the indications are controversial for the dorsal fixation of fractures in thoracic and lumbar spine. Thoraco-lumbar pains with radiation into the lower extremities or the existence of an Intraspinous haemorrhage should be considered, but the most circumstantial option is the instability in the affected segments with regarding of the spinal cord compression with and without neurological and sensorimotoric deficits or radicular symptoms.

Development of transpedicular screw fixation techniques and instrumentation systems has brought short-segment instrumentation (fixation of one normal vertebra above and below an injured segment) into general clinical practice<sup>1</sup>.

After King<sup>2</sup> initially reported vertebral body screw fixation through the transfacet approach to the lumbar spine in 1944, Boucher<sup>3</sup> introduced the way to place screws into the vertebral body through the pedicle in 1958. Since pedicle screw fixation became widespread, as described by Roy-Camille<sup>4</sup> and others in 1963, pedicle screws have been used widely in diseases of the lumbar spine<sup>5</sup>. The optimal management of thoracolumbar fractures continues to be a matter of controversy<sup>6,7</sup> (Table 1).

The transpedicular short-segment construct represents an attempt to restore the anterior column without the need for anterior strut grafting or plate fixation, avoiding extensive arthrodesis

Table 1. American Spine Injury Association Impairment Scale

Grade	Description
A	Complete: no motor or sensory function is preserved
B	Incomplete: sensory but no motor function is preserved below the neurological level
C	Incomplete: motor function is preserved below the neurologic level, & the majority of key muscles below the neurological level have a muscle grade <3/5
D	Incomplete: motor function is preserved below the neurological level, & the majority of key muscles below the neurological level have a muscle grade >3/5
E	Normal: motor % sensory function is normal

of the motion segments. The use of pedicle screws, which can minimize the range of spinal segments to reduce damage to soft tissues and increase the rate of synostosis better than fixation using hooks and wires, expands the excellent functionalities of pedicle screws reported by studies<sup>8</sup>. To date, various unfavourable results have been reported with this method<sup>9-11</sup>. Those who suggest temporizing treatments insisted that they could achieve satisfactory results only by treatments using postures and long-term relaxations<sup>11-14</sup>. However, others who suggest surgical treatment, patients could expect to become mobile early, perform rehabilitative remedies, overcome anatomic fractures, and improve, in most cases, nervous functions by using

decompression and fixation<sup>9,15</sup> (Figure 1). Because of the increasing number of patients with surgically treated injuries of the spine it's important to answer the question of indication for hardware removal. In the cervical spine and after anterior instrumentations of the thoracic and lumbar spine hardware removal is only indicated as part of the management of postoperative complications<sup>12-23</sup> (Figure 2).

After dorsal instrumentation for fractures of the thoracic and lumbar spine, implant-associated discomfort is possible. In addition, in non-fusion procedures there is the risk of implant failure. In these cases the hardware should be removed.

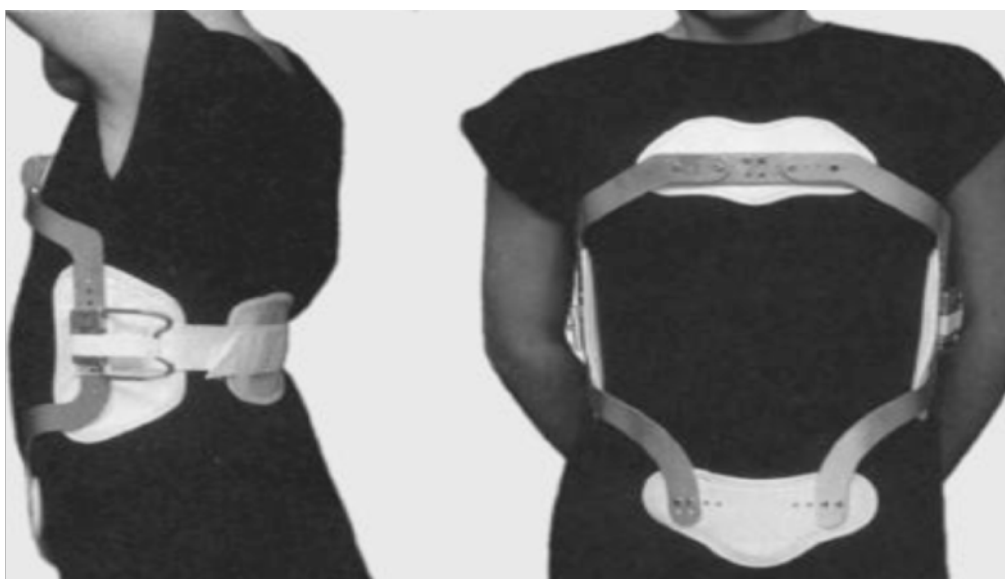

Figure 1: Immobilization and / or Thoracolumbar orthosis

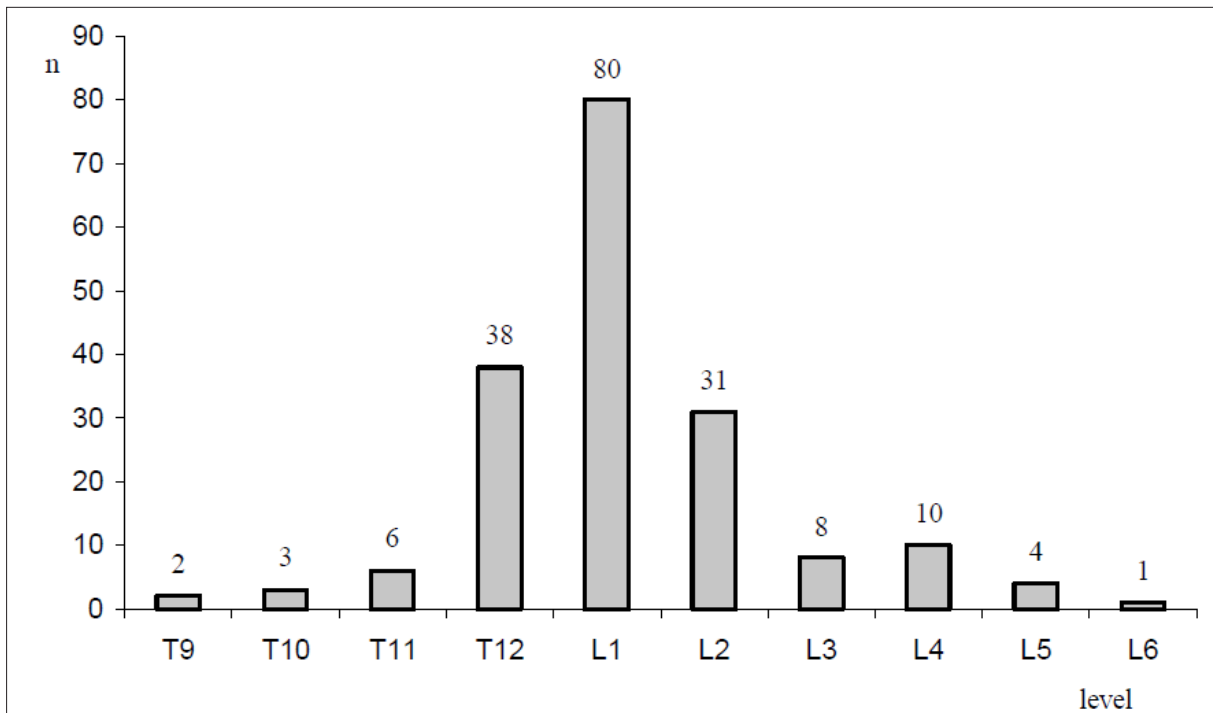


Figure 2. Fracture levels in patients with thoracic and lumbar spine fractures.

Because of the increasing number of patients with surgically treated injuries of the spine we more often have to answer the question of indication for hardware removal. In the cervical spine and after anterior instrumentations of the thoracic and lumbar spine hardware removal is only indicated as part of the management of postoperative complications. After dorsal instrumentation for fractures of the thoracic and lumbar spine, implant-associated discomfort is possible. In addition, in non-fusion procedures there is the risk of implant failure. In these cases the hardware should be removed. The consolidation of the thoracic and lumbar fractures is achievable normally after 12 months. To avoid the possibilities of complications of foreign body, the internal fixation has been removed, when the patient was totally free from any injury related symptoms. If the consolidation of the fracture is in doubt, a preoperative CT scan is useful. This study evaluates surgical outcome from the removal of the short segment pedicle screw fixation in 51 patients with thoracolumbar spine fractures, whereas until now in the

literature this issue hasn't been oftentimes reported<sup>22-52</sup>.

#### **MATERIAL AND METHODS**

Between 2005 and 2011 we have treated 51 cases (28 thoracal, 23 lumbar), whereas we performed a dorsal approach and implantation of an internal fixateur in one segment. The removal of the internal fixation (second surgery) has been performed approximately after 12 months. Only patients free from symptoms related to the initial fractures in the thoracic and lumbar spine have been considered. An X-ray a.p. and lateral and a CT-scan of the affected region have been performed preoperatively. The height of the fractured vertebral body has been maintained. The mean age was 42 years, 29 males, 22 females (Table 2).

Table 2. Levels of the thoracic and lumbar spinal fractures.

Level	n
T 9	3
T 10	2
T 11	2
T 12	21
L 1	17
L 2	5
L 3	1
Total	51

In the following two cases should be exemplary for the clinical course of the investigated patients.

Case 1: Farmer, male, 67 years old, L1-fracture, fall from tree. Recognizable bony narrowing in plain lateral radiographs. Follow-up 24 months after initial surgery after t= 0, and removal of the internal fixation after 9 months (Figure 3).

Case 2: 23-year-old female sustained a motor vehicle accident as an unrestrained passenger. Clinically, she presented with an incomplete paraplegia (ASIA C) and an incomplete conus-cauda syndrome. The initial CT (a-d) scan demonstrates an unstable complete burst fracture of

L1 (Type A3.3). The 3D reconstruction (a, b) gives a good overview of the degree of comminution and the deformity; the posterior fragment is best visualized in the lateral 2D reconstruction (c) and the axial view (d). In an emergency procedure, the myelon was decompressed by laminectomy and the fracture was reduced and stabilized with an internal fixator (e-h). Interestingly, the prone position alone (e) reduced the fracture to a certain degree when compared to the CT scan taken with the patient in a supine position. With the internal fixator (RecoFix), the anatomical height and physiological alignment was restored (f) and the posterior fragment was partially reduced (g, h). After 12 months the patient could walk with assistance, with weakness in the lower extremities of 3-4/5

**RESULTS**

Prior to the second surgery 9 patients had pain > 50 on VAS, postoperatively 5. Motor deficits 6 prior and 5 after surgery. Just 8 Patients had sensory deficits prior, but just 6 after the 2. surgery. The ability to work after the 2. Surgery was: 24 full time, 12 part time, 7 unable to work and 7 retired. Back to work ratio 86%. About 29 out of 51 patients were available for re-examination and interview 6 months after the explanation of the internal fixation. 37 were happy with the outcome, 14 patients

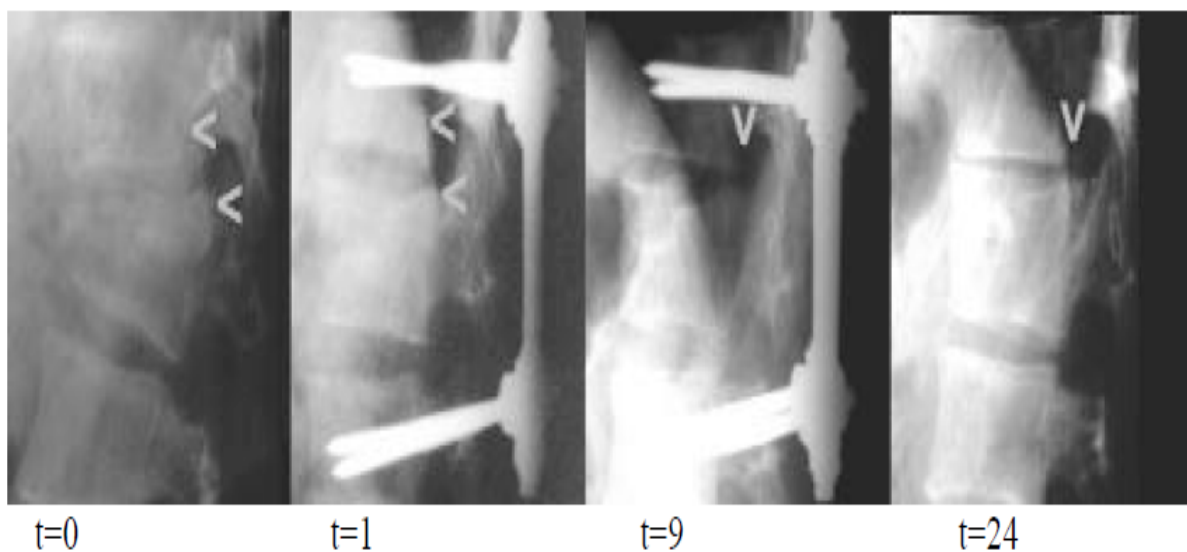


Figure 3. Recognizable bony narrowing in plain lateral radiographs. Follow-up 24 months after initial surgery after t= 0, and removal of the internal fixation after 9 months.

had recognized no differences in their daily life activities. In the radiological findings after the second surgery there were no signs of instability in 49 patients, in 2 patients with fixation in the thoracic spine slightly compression of the vertebral bodies without a surgical consequence has been observed. No myelopathy had been occurred. Complications: In just 2 patients with rebleeding requiring surgical evacuation on the day of surgery. Otherwise uneventful further recovery. And so far no single case of infection has been observed.

## DICUSSION

Until now there is in the literature no oftentimes reports about the removal of the internal fixation in the thoracic and lumbar spine<sup>39-49, 51-52</sup>. In the patients, who have been treated with the second operation this management has been successful so far the patient were followed up during the first 12 months after the 2. Operation, which was an elective procedure. Further investigations and studies concerning this management should be performed in the next future.

## CONCLUSION

The explantation of the thoracic and lumbar monosegmental internal fixation is not associated with an increased risk for the patients as compared to not removal of this fixation. The removal of the internal fixation appears to be particularly practicable in younger age groups up to 65 years. The long term effect of this operation technique is unclear as of yet.

## REFERENCES

1. Jeffrey WP, Joel RL, Eldin EK, et al. Successful Short-Segment Instrumentation and Fusion for Thoracolumbar Spine Fractures A Consecutive 4 1/2-Year Series. *Spine* 2000;25:1157-69.
2. King D. Internal fixation for lumbosacral fusion. *Am J Surg* 1944;66:357-67.
3. Boucher HH. A method of spinal fusion. *J Bone Joint Surg* 1959;41:248.
4. Roy-Camille R, Saillant G, Mazel C: Internal fixation of the lumbar spine with pedicle screw plating. *Clin Orthop* 1986;203:7-17.
5. Han IH, Song GS. Thoracic Pedicle Screw Fixation and Fusion in Unstable Thoracic Spine Fractures. *J Korean Neurosurg Soc* 2002;32:334-40.
6. Ahmet A, Emre A, Muharrem Y, et al. Short-Segment Pedicle Instrumentation of Thoracolumbar Burst Fractures Does Transpedicular Intracorporeal Grafting Prevent Early Failure? *Spine* 2001;26:213-7.
7. Been HD, Bouma GJ. Comparison of two Types of Surgery for Thoraco-Lumbar Burst Fractures: Combined Anterior and Posterior Stabilization vs. Posterior Instrumentation Only. *The Netherlands Acta Neurochir (Wien)* 1999;141:349-57.
8. Kothe R, Panjabi MM, Liu W. Multidirectional instability of the thoracic spine due to iatrogenic pedicle injuries during transpedicular fixation. A biomechanical investigation. *Spine* 1997;22:1836-42.
9. Aebi M, Etter C, Kehl T. Stabilization of the lower thoracic and lumbar spine the internal spine skeletal fixation system. Indication, technique, and first results of treatment. *Spine* 1987;12:544-51.
10. Denis F, Armstrong GWD, Searis K. Acute thoracolumbar burst fractures in the absence of neurologic deficits. *Clin Orthop Relat Res* 1984;189:142-9.
11. Gertzbein SD, Court-Brown CM, Marks P. The neurologic outcome following surgery for spinal fractures. *Spine* 1988;13:641-4.
12. Cantor JB, Labwohl NH, Garvey T. Nonoperative management of stable thoracolumbar burst fractures with early ambulation and bracing. *Spine* 1993;18:971-6.
13. Dickson JH, Harrington PR, Erwin WD. Results of reduction and stabilization of the severely fractured thoracic and lumbar spine. *J Bone Joint Surg* 1978;60:799-805.
14. Jacobs RR, Casey MP. Surgical management of thoracolumbar spinal injuries. *Clin Orthop Relat Res* 1984;189:22-35.
15. Bradford DS, Akbarnia BA, Winter RB. Surgical stabilization of fractures and fracture dislocation of the thoracic spine. *Spine* 1977;2:85-196.
16. McCormack T, Karaikovic E, Gaines RW. The load-shearing classification of spine fractures. *Spine* 1994;19:1741-4.
17. Lee YS, Sung JK. Long-term Follow-up Results of Shortsegment Posterior Screw Fixation for Thoracolumbar Burst Fractures. *J Korean Neurosurg Soc* 2005;37:416-21.
18. Blauth M, Tscherne M. Therapeutic concept and results of operative treatment in acute trauma of the thoracic and lumbar spine : The Hanover experience. *J Orthop Trauma* 1987;1:240-52.
19. Farcy JP, Veidenbaum M, Glassman S. Sagittal index in management of thoracolumbar burst fractures. *Spine* 1990;15:958-65.
20. Sasso RC, Costler HB. Posterior Instrumentation and fusion for unstable fractures and fracture-dislocations of the thoracic and lumbar spine. *Spine* 1993;18:450-60.
21. James JY, Allen S, Christopher S, et al. The Treatment of Unstable Thoracic Spine Fractures with Transpedicular Screw



- Instrumentation: A 3-Year Consecutive Series. *Spine* 2002;27:2782-7.
22. Kim KS, Oh SH, Huh JS, et al. Dorsal Short-Segment Fixation for Unstable Thoracolumbar Junction Fractures. *J Korean Neurosurg Soc* 2006;40:249-55.
  23. Roy-Camille R, Saillant G, Salgado V. Osteogenesis of thoracolumbar spine fractures with metal plates screwed through the vertebral pedicle. *Reconstr Surg Traumatol* 1976;15:2-16.
  24. Dorr LD, Harvey JP, Nickel VL. Clinical review of the early stability of spine injuries. *Spine* 1982;7:545-53.
  25. Frankel H, Hancock DO, Hyslop G. The value of postural reduction in the initial management of closed injuries of the spine with paraplegia and tetraplegia. *Paraplegia* 1969;7:179-92.
  26. Patrick T, Russel CH, Christian AL, et al. Functional and radiologic outcome of thoracolumbar and burst fractures managed by closed orthopedic reduction and casting. *Spine* 2003;28:2459-65.
  27. Chun SW, Hwang JH, Sung JK, et al. Pedicle Screw Fixation and Posterolateral Fusion for Thoracolumbar Spine Fracture. *J Korean Neurosurg Soc* 1999;28:644-8.
  28. Park P, Garton HJ, Gala VC, et al. Adjacent segment disease after lumbar or lumbosacral fusion. *Spine* 2004;29:1938-44.
  29. Hyun SJ, Lim YB, Hong HJ, et al. Predictable risk factors for adjacent segment degeneration after lumbar fusion. *J Korean Neurosurg Soc* 2007 41:88-94.
  30. Aota Y, Kumano K, Hirabayashi S. Postfusion instability at the adjacent segments after rigid pedicle screw fixation for degenerative lumbar spinal disorders. *J spine Disord* 1995;8:464-73.
  31. Bolesta MJ, Rehtine II GR. Fractures and dislocations of the thoracolumbar spine. In: Bucholz RW, Heckman JD. *Rockwood and Green's Fractures in adults*. 6th edition. USA. Lippincott Williams & Wilkins; 2008:1405-65.
  32. Vaccaro AR, Kim DH, Brodke DS, et al. Diagnosis and management of thoracolumbar spine fractures. *Instr Course Lect* 2004;53:359-73.
  33. Mirza SK, Chapman JR. Principles of management of spine injury. In: Bucholz RW, Heckman JD. *Rockwood and Green's Fractures in adults*. 6th edition. USA. Lippincott Williams & Wilkins 2008; 1295-1323.
  34. Butt RM, Shams S, Habib A, et al. Epidemiology of spinal injuries. *Pakistan J Neurol.* 1997; 3: 20-5.
  35. Bensch FV, Koivikko MP, Kiuru MJ, Koskinen SK. The incidence and distribution of burst fractures. *Emerg Radiol* 2006; 12:124-9.
  36. Vaccaro AR, Kim DH, Brodke DS, et al. Diagnosis and management of thoracolumbar spine fractures. *J Bone & Joint Surg Br* 2003; 85:2456-70.
  37. Berry GE, Adams S, Harris MB. Are plane radiographs of spine necessary after blunt trauma? Accuracy of screening torso computer tomography in thoracolumbar spine fracture diagnosis. *J Trauma*. 2005; 59: 1410-3.
  38. Karaikovic EE, Pacheco HO. Treatment options for thoracolumbar spine fractures. *Bosn J Basic Med Sci* 2005; 5: 20-6.
  39. Kervin AJ, Frykberg ER, Schnico MA. The effect of early spinal fixation on non neurologic outcome. *J Trauma* 2005; 58: 15-21.
  40. Krbec M, Stulik J. Treatment of thoracolumbar spinal fractures using internal fixations. *Acta Chir Orthop Traumatol Cech* 2001; 68: 77-84.
  41. Razaq M, Mahmud MM, Hayzam MY, et al. Short segment posterior instrumentation, reduction and fusion of unstable thoracolumbar burst fractures - a review of 26 cases. *Med J Malaysia*. 2000; 55: 9-13.
  42. Hiwatashi A, Sidhu R, Lee RK, et al. Kyphoplasty vs. vertebroplasty to increase vertebral body height - a cadaveric study. *Radiology* 2005; 237:1115-9
  43. Farcy JP, Weidenbaunn M, Glassman SD. Sagittal index in management of thoracolumbar burst fractures. *Spine* 1990; 15: 958-65. Defino HL, Scarparo P Fractures of thoracolumbar spine: Monosegmental fixation. *Injury* 2005;36:90-7.
  44. Steib JP, Aoui M, Mitulescu A, et al. Thoracolumbar fractures surgically treated by "in situ" contouring. *Eur Spine J* 2006; 12:1823-32.
  45. Dai LY, Yao WF, Cui YM, Zhou Q Thoracolumbar fractures in patients with multiple injuries: diagnosis and treatment - a review of 147 cases. *J Trauma* 2004; 56: 348-55.
  46. Thomas KC, Bailey CS, Dvorak MF, et al. Comparison of operative and nonoperative treatment for thoracolumbar burst fractures in patients without neurological deficit: a systematic review. *J Neurosurg Spine* 2006;4:351-8.
  47. Khan I, Nadeem M, Rabbani ZH. Thoracolumbar junction injuries and their management with pedicle screws. *J Ayub Med Coll Abbottabad* 2007; 19:7-10
  48. Afzal S, Mir MR, Halwai MA, et al. (VSP) instrumentation for the surgical management of thoracolumbar spinal fractures. (a study of 20 cases). *JK-Practitioner* 2002; 94:227-30
  49. Tezer CM, Ozturk M, Aydogan C, et al. Surgical outcome of thoracolumbar burst fractures with flexion-distraction injury of the posterior elements. *International Orthopaedics* 2005; 29: 347-50
  50. Helton LA, Defino Fabiano RTC. Low thoracic and lumbar burst fractures: radiographic and functional outcomes *Eur Spine J* 2007 16:1934-1943.
  51. Starkweather A. Posterior Lumbar Interbody Fusion. An Old Concept with New Techniques. *J Neurosci Nurs* 2006;38:13-30.
  52. Hardware removal after spinal instrumentation > Baron HC, Ochs BG, Stuby FM, Stoecke U, Badke A. *Unfallchirurg* 2012 Apr;115(4):339-42.